

Protrusio acetabulae as a sequel to septic arthritis of the hip with obturator internus pyomyositis

Gaurav Gupta, Qaisur Rabbi, Vikas Bohra and Maulin M. Shah

Pyomyositis is defined as a pyogenic infection of skeletal muscles principally caused by *Staphylococcus aureus*. It can present either primarily without any associated soft tissue or bone infection or secondary to any surrounding or distant infection focus. Hip pericapsular pyomyositis is one of the most common types of primary pyomyositis. Although many cases are increasingly being described both in tropical and temperate climates, there is no published study regarding the sequelae of untreated pericapsular pyomyositis around the hip joint. The purpose of this study is to describe the sequelae of unaddressed obturator internus abscesses in four adolescent patients and compare their outcome with patients where obturator abscess was also drained using Vanderbilt medial approach. A retrospective study was done with eight patients divided equally into two groups. All the patients were diagnosed as septic arthritis with pyomyositis of obturator internus. Group 1 includes patients treated in between 2012 and 2014 with only hip arthrotomy through anterior approach. Group 2 includes patients treated after 2014 with anterior hip arthrotomy along with drainage of obturator internus abscess. All patients in group 1 had frequent episodes of pain in the first postoperative year with persistent restriction of hip range of motion. Two patients required re-drainage of the hip joint within the first month of indexed surgery. Final follow-up (average 6 years) X-rays revealed grade 2

protrusio acetabuli in three cases and grade 3 in one case as per the Sotelo-Garza and Charnley classification. In contrast to the group 1, group 2 patients had an excellent outcome with an average Iowa Hip Score of 93 at average follow-up of 4.25 years with near normal range of motion, no radiological deterioration and residual pain. The possibility of pericapsular pyomyositis should always be kept in mind, in older children with acute hip pain. A high index of suspicion is required for its early diagnosis. MRI is the gold standard investigation for confirming diagnosis and planning the preferred early surgical treatment. Safe and effective surgical drainage of obturator internus abscess through a minimally invasive Vanderbilt medial approach may prevent long-term sequelae of chronic pain, protrusio acetabuli and secondary osteoarthritis. *J Pediatr Orthop B XXX: 000–000* Copyright © 2020 Wolters Kluwer Health, Inc. All rights reserved.

Journal of Pediatric Orthopaedics B 2020, XXX:000–000

Keywords: hip, Iowa, obturator, protrusio acetabulae, septic arthritis, vanderbilt

OrthoKids Clinic, Ahmedabad, Gujarat, India

Correspondence to Maulin M. Shah, MBBS, MS Ortho, DNB Ortho, OrthoKids Clinic, 7th Floor, Golden Icon, Opp. Medilink Hospital, Near Shivranjini Flyover, Satellite, Ahmedabad 380015, India
Tel: +9825026360; e-mail: maulinmshah@gmail.com

Received 16 April 2020 Accepted 21 September 2020

Introduction

Pyomyositis is defined as a pyogenic infection of skeletal muscles principally caused by *Staphylococcus aureus* [1]. It was first described by Scriba in 1885 [2]. It can present either primarily without any associated soft tissue or bone infection [3] or secondary to any surrounding or distant infection focus. Primary pyomyositis is synonymous with infective myositis, tropical myositis, pyogenic myositis and myositis purulenta tropica [4–11]. It is considered to be more common in tropical countries in comparison to the temperate nations [1,13,14]. Primary pyomyositis can affect individuals of any age but it is most commonly seen in patients between the second and third decades of life [3]. Hip pericapsular pyomyositis is one of the most common types of primary pyomyositis. It is difficult to distinguish it from septic arthritis of hip due to similar

clinical features and blood markers [6–19]. In a study by Menge *et al.* [15], obturator internus and externus were the most commonly involved pelvic girdle muscles. In early stages, these cases could be managed nonoperatively, with empirical antibiotics. However, drainage is required in cases of MRI proven abscess which fail to respond to antibiotics [15]. Although many cases are increasingly being described both in tropical and temperate climates, there is no published study regarding the sequelae of untreated pericapsular pyomyositis around the hip joint. The purpose of this study is to describe the sequelae of unaddressed obturator internus abscesses in four adolescent patients and compare their outcome with patients where obturator abscess was also drained using Vanderbilt medial approach [15] (modified obturator approach).

Materials and methods

This study was done in a private hospital in western India with eight patients divided into two groups. Institutional

Supplemental Digital Content is available for this article. Direct URL citations appear in the printed text and are provided in the HTML and PDF versions of this article on the journal's website, www.jpob.com.

review board approval was obtained for the study. All patients diagnosed with septic arthritis and pyomyositis of obturator internus with minimum 2 years of follow-up were included in the study. Group 1 included patients treated in between 2012 and 2014 with only hip arthrotomy through anterior approach. Group 2 included patients treated after 2014 with hip arthrotomy through anterior approach along with Vanderbilt Medial Approach to drain pyomyositis of obturator internus. Supplement digital content 1, <http://links.lww.com/JPOB/A54>. For Vanderbilt medial approach [15], patient was positioned supine with a sandbag under the opposite buttock and the affected hip kept slightly abducted. A 4-cm vertical incision was placed along the posterior border of adductor longus tendon. Adductor longus was retracted anteriorly to expose the Adductor brevis and overlying posterior branch of obturator nerve. The course of obturator nerve was followed proximally to the obturator foramen. A blunt hemostat was used to pierce through the obturator foramen under image intensifier guidance. Further, the hemostat was advanced proximally and medially towards the quadrilateral plate. Hemostat wide opened and withdrawn to drain the abscess. Lavage of the area was done by inserting an infant feeding tube. A negative suction drain was placed in all the patients. In group 2 patients, double drains were inserted. Average time of drain removal was 3 days in both the groups. Intravenous third-generation cephalosporins were started empirically immediately after the arthrotomy and sample collection. Antibiotics were later changed according to the culture reports and continued till C-reactive protein (CRP) normalised. Weight-bearing was started as per tolerance and comfort of the patients. Patients were followed every 3 months for the first year and annually thereafter. Outcome of procedure was determined by using Iowa Hip Scores, range of motion, radiological appearance and residual pain at final

follow-up. The groups were not compared statistically due to smaller number of patients in either of the group.

Results

Group 1 consisted of four patients (two male and two female) with average age of 12.6 years who presented to us between 2012 and 2014 with pain in the groin and around the hip joint, fever and inability to bear weight over the affected limb. There was no history of trauma or overactivity, no complaint of burning micturition and polyuria. None of the two female patients had vulvar swelling. Inguinal lymphadenopathy was present in the two male patients and none of the four patients had any skin lesions. The average duration of symptoms was 13 days. Physical examination was positive for raised local temperature (average body temperature at presentation was 101°F/38.3°C) with restricted and painful hip motion. There was no distal neurovascular deficit. On the basis of clinical examination, we suspected septic arthritis of hip as the diagnosis. Anteroposterior radiograph of the pelvis was normal in two patients. In the other two patients, there was relatively increased hip joint space on the involved side. Blood investigations revealed elevated erythrocyte sedimentation rate, CRP and white blood cell counts (Table 1). Blood culture was positive for *S. aureus* in two out of four patients. MRI evaluation of the hip was positive for hip joint effusion along with incidental finding of edema and fluid collection within the substance of obturator internus muscle, suggestive of obturator internus abscess. In two patients, it was suggestive of a horse-shoe shaped abscess connecting the hip joint with the obturator internus via lesser sciatic notch (Figs 1 and 4).

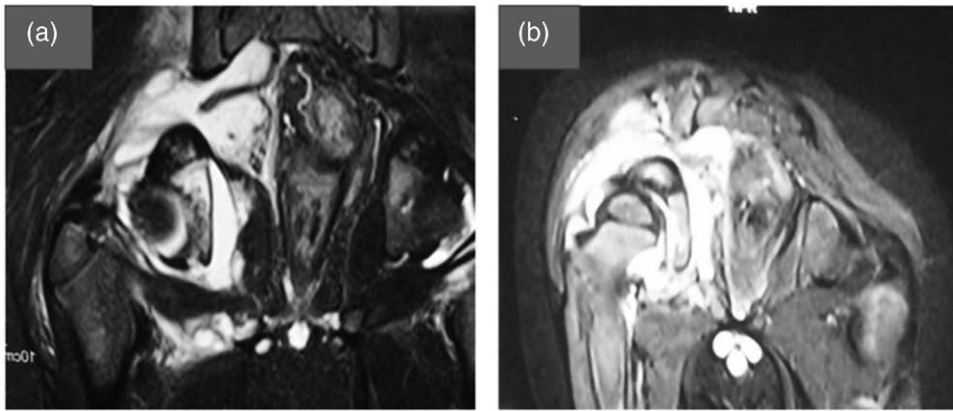
Hip arthrotomy was performed in these cases through anterior approach. Since the obturator internus abscess

Table 1 Patient details

Sl. no.	Age (years)	Sex	Site	Duration of symptoms (before surgery)	TLC	CRP	ESR	Management	Culture report	Hospital stay (days)	Complications	Duration of follow-up (years)	Iowa Hip Score
1.	12	M	R	15 days	13 000	74	33	Arthrotomy	MRSA	24	Restricted ROM, Re drainage, LLD of 1.5 cm.	6.5	70
2.	11	M	R	12 days	12 760	68	38	Arthrotomy	MRSA	11	Restricted ROM, Limp, LLD of 1 cm.	6	66
3.	14.5	F	L	11 days	12 840	78	42	Arthrotomy	No growth	11	Restricted ROM, Limp.	8	72
4.	13	F	L	14 days	13 220	82	47	Arthrotomy	MSSA	17	Restricted ROM, Re drainage, LLD of 1.5 cm.	3.5	69
5.	12	M	R	5 days	13 725	88	50	Arthrotomy + VMA	MSSA	8	None	4	95
6.	13.5	F	R	8 days	15 600	78	48	Arthrotomy + VMA	MRSA	7	None	4.5	91
7.	11.5	M	L	6 days	16 000	75	36	Arthrotomy + VMA	MRSA	5	None	5	96
8.	11	M	L	4 days	14 600	70	32	Arthrotomy + VMA	No growth	5	None	3.5	90

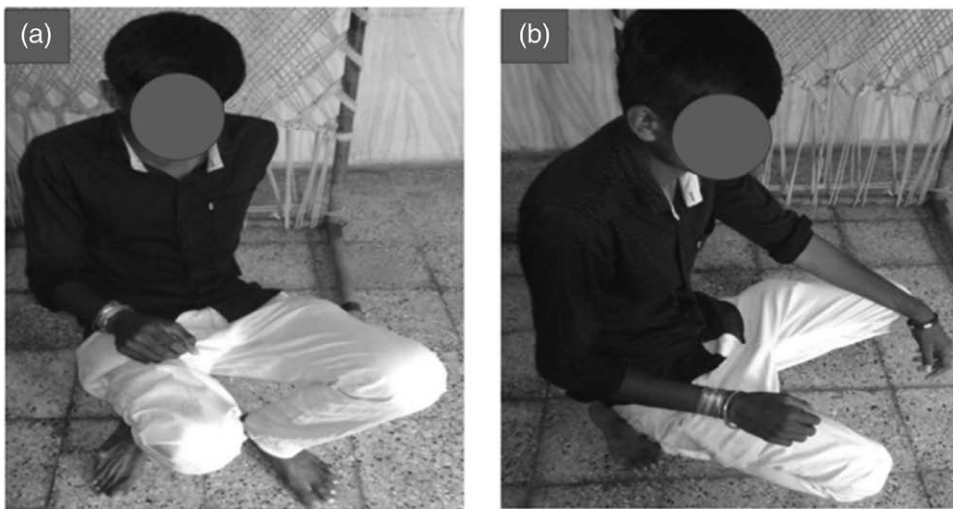
CRP, C-reactive protein (milligram per litre); ESR, erythrocyte sedimentation rate (millimetre at the first hour); F, female; L, left; LLD, limb length discrepancy; M, male; MRSA, methicillin-resistant *Staphylococcus aureus*; MSSA, methicillin-sensitive *Staphylococcus aureus*; R, right; ROM, range of motion; TLC, total leucocyte count (per cubic millimetre); VMA, Vanderbilt Medial Approach.

Fig. 1



A 12-year-old boy (case 1) presented to us with complaint of pain over right hip and inability to bear weight over right lower limb for 15 days. He has history of high grade fever (101°F). (a and b) Axial and coronal MRI of the affected hip at the time of presentation depicting pericapsular pyomyositis (obturator abscess) in association with septic arthritis of the right hip.

Fig. 2



(a and b) Clinical photographs of patient (case 1) at 6.5 years follow-up showing inability to sit cross-legged and squat. His IOWA Hip Score at final follow-up was 70.

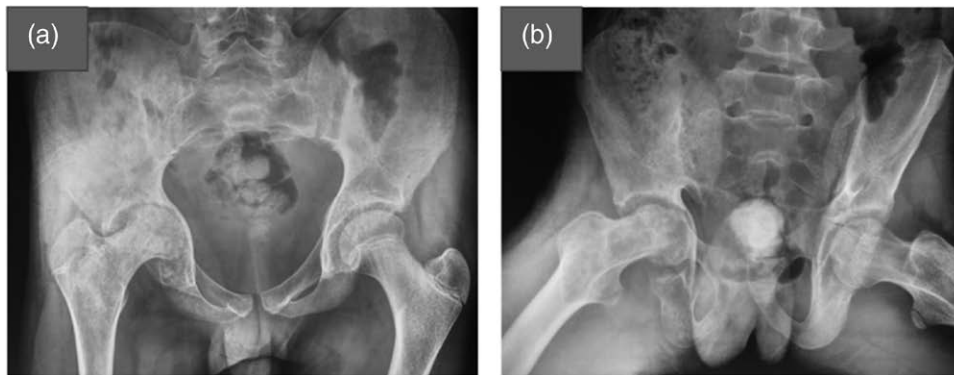
communicated with hip joint, we expected it to drain through the hip arthrotomy via anterior approach. In other two patients, there was no communication with the hip joint and obturator internus abscess, only anterior hip arthrotomy was done as the obturator abscess was not considered significant for drainage. Average duration of antibiotics was 2.25 weeks for intravenous and 4 weeks for oral in group 1 patients.

Group 2 also consisted of four patients (three male and one female) with average age of 12 years who presented to us between 2014 and 2016 with septic arthritis and obturator internus abscess. The demographic details of

group 2 patients are mentioned in detail in Table 1. After 2014 (group 2), we adopted a dual approach where anterior hip arthrotomy was followed by Vanderbilt medial approach [15] to drain the Obturator internus abscess directly. Frank pus was drained in all four patients. The results of both groups are compared in Table 2.

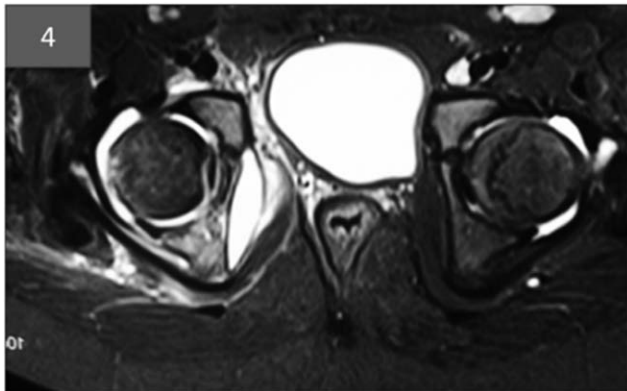
Both groups of patient's demographics and clinical details are described in Table 1. For group 1, average follow-up was of 6 years. All patients in this group had frequent episodes of pain in the first postoperative year with persistent restriction of hip range of motion. Their blood markers took 3.4 weeks to normalise (range, 22–26 days).

Fig. 3



(a and b) X-ray pelvis with both hips of patient (case 1) at 6.5 years follow-up showing severe chondrolysis and protrusion acetabuli (Sotelo and Garza Type 2).

Fig. 4



Axial MRI of both hips of 11 years old boy (case 2) at the time of presentation suggestive of Right hip pericapsular pyomyositis (obturator internus abscess).

Two patients required re-drainage of the hip joint within the first month of indexed surgery. Average duration of hospital stay was 15 days. Final follow-up X-rays revealed grade 2 protrusio acetabuli in three cases and grade 3 protrusio in one case as per the Sotelo-Garza and Charnley classification [20] (Table 3, Figs 3 and 5). Generalised chondrolysis of femoral articular surface was also evident in all patients. All the patients had fused growth plates and there was an average limb length discrepancy of 1 cm. Their average Iowa Hip Score [21] at final follow-up was 69. All patients limped while walking, and they were unable to squat and sit cross-legged, both of which are an essential part of daily life style in India (Fig. 2).

In contrast to group 1, group 2 patients had excellent outcome with an average Iowa Hip Score of 93 at average follow-up of 4.25 years. In group 1, average time for weight bearing was 10 days and in group 2, it was 5 days. Group

Table 2 Results in both the groups

Particulars	Group 1 (only arthroscopy)	Group 2 (arthrotomy with VMA)
Average age at presentation	12.6 years	12 years
Average duration of symptoms	13 days	5.75 days
Average temperature at presentation	101°F (38.3°C)	101.5°F (38.6°C)
Male: female	1:1	3:1
Average TLC	12 955 per cubic millimetres	14 981 per cubic millimetres
Average CRP	75.5 milligram per litre	77.75 milligram per litre
Average ESR	40 millimetre after first hour	41.5 millimetre after first hour
Average time for normalisation of blood investigations	24 days	14 days
Average Iowa Score	69.25	93
Average follow-up	6 years	4.25 years
Need for repeat drainage	2 cases	Not required
Restricted range of motion	4/4	0/4
Persistent limp	4/4	0/4
Protrusio acetabuli (Sotelo-Garza Classification)	4/4 (Grade 2 in 3 and Grade 3 in 1)	None

CRP, C-reactive protein (milligram per litre); ESR, erythrocyte sedimentation rate (millimetre at the first hour); TLC, total leucocyte count (per cubic millimetre); VMA, Vanderbilt Medial Approach.

1 patients took longer time to tolerate weight bearing. Group 2 patients demonstrated near normal range of motion, no radiological deterioration and residual pain (Figs 6 and 7).

Discussion

Hip pericapsular pyomyositis with obturator internus and externus abscess and its management are reported with increasing frequency [13,15,22–28]. However, to our knowledge, there is no literature regarding the outcome of untreated obturator internus abscess till now. The largest series of 53 cases regarding epidemiology, diagnosis, and treatment of hip pericapsular pyomyositis was published by Mignemi *et al.* [19] in 2014. They concluded that existing clinical algorithms were unable

to differentiate between septic arthritis and pericapsular pyomyositis. They also inferred MRI to be the most efficient tool in distinguishing septic arthritis from pericapsular pyomyositis and recommended inclusion of MRI as a part of clinical algorithm. In our series, MRI demonstrated co-existing collection in the hip joint and obturator internus muscle, although it was impossible to confirm which of these was the primary site of affection.

Various authors have reported different clinical examination findings to be specific for obturator externus/internus abscesses including increased pain in external rotation of

hip [12], restriction of internal rotation of hip [13,27], skin lesions and labia majorum swelling [24]. However, none of them is pathognomonic of obturator muscle abscesses and thus cannot be used for establishing its diagnosis. In a series of 22 cases of obturator internus abscess, King *et al.* found that the limitation of hip movements was not as severe as seen in septic arthritis of hip joint [29]. In our series, all the cases were late presenters with the involvement of both hip and obturator internus muscle with global restriction of hip motion. Patients mostly preferred to sit upright and denied lying down on the couch to avoid painful hip extension.

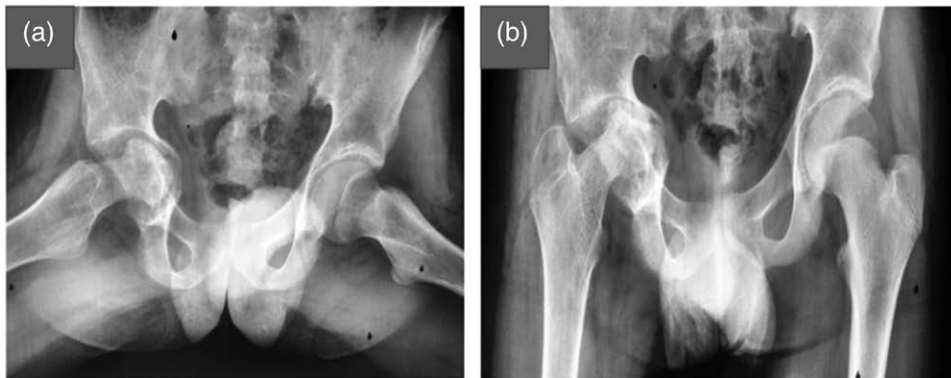
Samuel presented a detailed literature review regarding aetiology of protrusion acetabuli from 1824 to 2006. There was no mention of untreated obturator internus or pericapsular pyomyositis as a cause of secondary protrusion acetabuli [30]. None of the other previous literature has reported protrusio acetabuli as a complication of obturator internus abscess. Obturator internus arises from the rami surrounding the obturator foramen and the quadrilateral plate [31]. Untreated pyomyositis of this

Table 3 Sotelo-Garza and Charnley classification for protrusio acetabuli [20]

Grade	Protrusion (mm*)
0	None (0)
I	Mild (1–5)
II	Moderate (6–15)
III	Severe (>15)

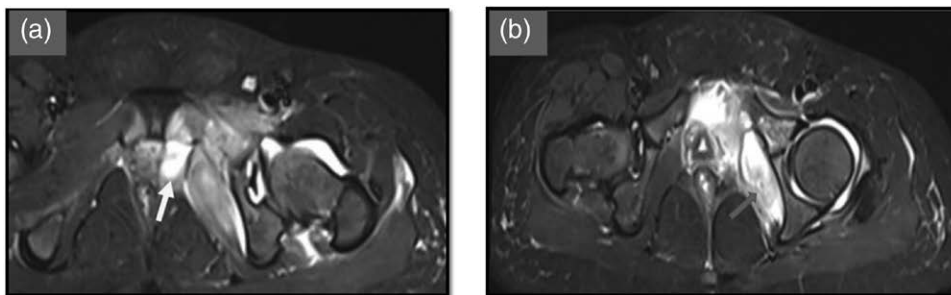
Sotelo-Garza and Charnley [20] used the Ilioischial line on an anteroposterior pelvis radiograph as a reference point from which the location of medial acetabular wall was measured. mm* – millimetre.

Fig. 5



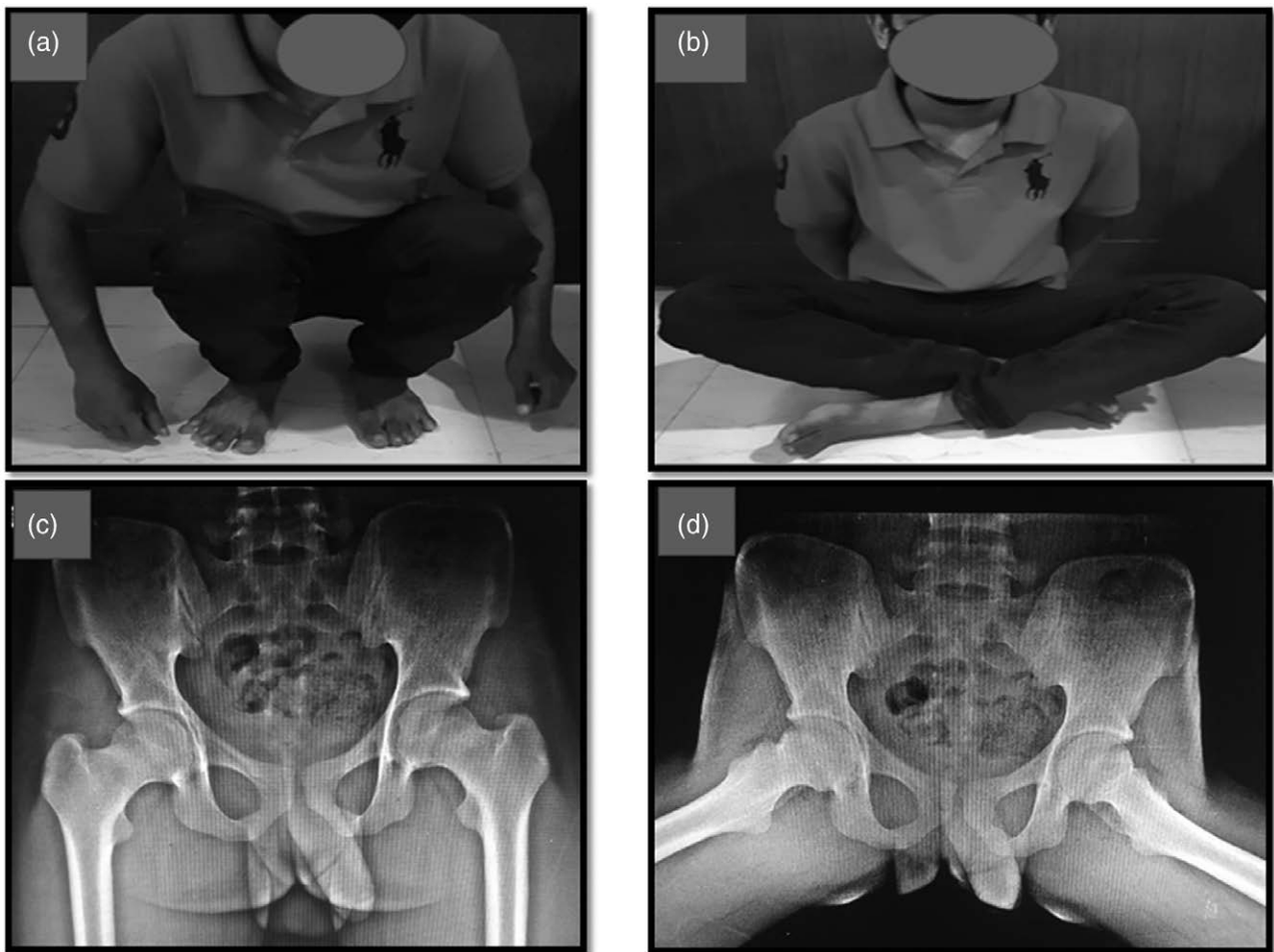
(a and b) X-ray pelvis with both hips of patient (case 2) at 6 years follow-up showing severe chondrolysis and protrusion acetabuli (Sotelo-Garza and Charnley Type 3).

Fig. 6



(a and b) Sagittal sections of MRI both hips of case 7 showing Left obturator abscess with septic arthritis of left hip joint.

Fig. 7



(a–d) Clinical and radiological images of a patient (case 7) at 5 years follow-up showing comfortable squatting and cross-legged sitting with bilaterally similar hip movements. X-ray pelvis with both hips, anteroposterior and Frog-lateral views showing complete healing with no protrusion and chondrolysis of the left hip joint. It was managed with Arthrotomy and Vanderbilt Medial Approach. His Iowa Hip Score at final follow-up was 96.

muscle can lead to erosion of the quadrilateral plate making it thin and weak. This may have caused the medial migration of femoral head on weight bearing and protrusio acetabuli in our series.

Chondrolysis of the hip can be multifactorial. In our series, it could have been due to delayed presentation secondary to the septic arthritis of the hip. Another probable cause could be chronic drainage of the unaddressed obturator internus abscess into the hip joint through the lesser sciatic notch. The combination of protrusio acetabuli with chondrolysis restricted already compromised hip motion.

Menge *et al.* [15] have demonstrated safe access to obturator internus and externus muscles for abscess decompression and drain placement with successful results through Vanderbilt medial approach. They attributed this good

outcome to direct drainage of the abscess with less soft tissue trauma in comparison to other approaches used for similar purpose. We also were able to achieve adequate drainage and avoid the aforementioned complications of unaddressed abscess using this approach.

Conclusion

The possibility of pericapsular pyomyositis should always be kept in mind, in older children with acute hip pain. A high index of suspicion is required for its early diagnosis. MRI is the gold standard investigation for confirming diagnosis and planning the preferred early surgical treatment. Safe and effective surgical drainage of obturator internus abscess through a minimally invasive Vanderbilt medial approach may prevent long-term sequelae of chronic pain, protrusio acetabuli and secondary osteoarthritis.

Acknowledgements

We would like to acknowledge Dr Dhiren Ganjwala, Dr Michael Millis, Dr Prasad Gourineni and Dr Hiroshi Kitoh for helping us in preparing this manuscript.

G.G. was involved in study design, performed measurements, statistical analysis and manuscript preparation. Q.R. involved in study design, performed measurements and statistical analysis. V.B. was involved in the study design and performed measurements. M.M.S. was responsible for study design, statistical analysis and manuscript preparation.

Conflicts of interest

There are no conflicts of interest.

References

- Cheidozi LC. Pyomyositis: review of 205 cases in 112 patients. *Am J Surg* 1979; **137**:255–259.
- Scriba J. Beitrag zur Aetiologie der myositis acuta. *Deutsche Zeit Chir* 1885; **22**:497–502.
- Ovadia D, Ezra E, Ben-Sira L, Kessler A, Bickels J, Keret D, et al. Primary pyomyositis in children: a retrospective analysis of 11 cases. *J Pediatr Orthop B* 2007; **16**:153–159.
- Altrocchi PH. Spontaneous bacterial myositis. *JAMA* 1971; **217**:819–820.
- Ashken MH, Cotton RE. Tropical skeletal muscle abscesses (pyomyositis tropicans). *Br J Surg* 1963; **50**:846–852.
- Chiendozi LC. Pyomyositis. Review of 205 cases in 112 patients. *Am J Surg* 1979; **137**:255–259.
- Echeverria P, Vaughn MC. "Tropical pyomyositis." A diagnostic problem in temperate climates. *Am J Dis Child* 1975; **129**:856–857.
- Geelhoed GW, Gray H, Alavi IA, Lattoo H. Pyomyositis – tropical and nontropical. *N Engl J Med* 1971; **284**:853–854.
- Goldberg JS, London WL, Nagel DM. Tropical pyomyositis: a case report and review. *Pediatrics* 1979; **63**:298–300.
- Levin MJ, Gardner P, Waldvogel FA. An unusual infection due to *Staphylococcus aureus*. *N Engl J Med* 1971; **284**:196–198.
- Shepherd JJ. Tropical myositis: is it an entity and what is its cause? *Lancet* 1983; **2**:1240–1242.
- Wong-Chung J, Bagali M, Kaneker S. Physical signs in pyomyositis presenting as a painful hip in children: a case report and review of the literature. *J Pediatr Orthop B* 2004; **13**:211–213.
- Birkbeck D, Watson JT. Obturator internus pyomyositis a case report. *Clin Orthop Relat Res* 1995; **316**:221–226.
- Schlech WF 3rd, Moulton P, Kaiser AB. Pyomyositis: tropical disease in a temperate climate. *Am J Med* 1981; **71**:900–902.
- Menge TJ, Cole HA, Mignemi ME, Corn WC, Martus JE, Lovejoy SA, et al. Medial approach for drainage of the obturator musculature in children. *J Pediatr Orthop* 2014; **34**:307–315.
- Kocher MS, Zurakowski D, Kasser JR. Differentiating between septic arthritis and transient synovitis of the hip in children: an evidence-based clinical prediction algorithm. *J Bone Joint Surg Am* 1999; **81**:1662–1670.
- Caird MS, Flynn JM, Leung YL, Millman JE, D'Italia JG, Dormans JP. Factors distinguishing septic arthritis from transient synovitis of the hip in children. A prospective study. *J Bone Joint Surg Am* 2006; **88**:1251–1257.
- Luhmann SJ, Jones A, Schootman M, Gordon JE, Schoenecker PL, Luhmann JD. Differentiation between septic arthritis and transient synovitis of the hip in children with clinical prediction algorithms. *J Bone Joint Surg Am* 2004; **86**:956–962.
- Mignemi ME, Menge TJ, Cole HA, Mencio GA, Martus JE, Lovejoy S, et al. Epidemiology, diagnosis, and treatment of pericapsular pyomyositis of the hip in children. *J Pediatr Orthop* 2014; **34**:316–325.
- Sotelo-Garza A, Charnley J. The results of Charnley arthroplasty of hip performed for protrusio acetabuli. *Clin Orthop Relat Res* 1978; **132**:12–18.
- Larson CB. Rating scale for hip disabilities. *Clin Orthop Relat Res* 1963; **31**:85–93.
- Godfroid N, Stalens JP. Thigh pain due to obturator internus phlegmon: a diagnostic challenge. *Eur J Pediatr* 1995; **154**:273–274.
- Gurbani SG, Cho CT, Lee KR, Powell L. Gonococcal abscess of the obturator internal muscle: use of new diagnostic tools may eliminate the need for surgical intervention. *Clin Infect Dis* 1995; **20**:1384–1386.
- Hakim A, Graven M, Alsaied K, Ayoub EM. Obturator internus abscess. *Pediatr Infect Dis J* 1993; **12**:166–168.
- Orlicek SL, Abramson JS, Woods CR, Givner LB. Obturator internus muscle abscess in children. *J Pediatr Orthop* 2001; **21**:744–748.
- Papadopoulos M, Chugh S, Fitzgerald R, Thomas RJ. Obturator internus pyomyositis. *Orthopedics* 2000; **23**:383–384.
- Souid AK, Sadowitz PD, Weiner L, Dubansky AS, Oliphant M. Obturator internus muscle abscess: a case report and review of the literature. *Am J Dis Child* 1993; **147**:1278–1279.
- Spiegel DA, Meyer JS, Dormans JP, Flynn JM, Drummond DS. Pyomyositis in children and adolescents: report of 12 cases and review of the literature. *J Pediatr Orthop* 1999; **19**:143–150.
- King RJ, Laugharne D, Kerslake RW, Holdsworth BJ. Primary obturator pyomyositis: a diagnostic challenge. *J Bone Joint Surg Br* 2003; **85**:895–898.
- Van De Velde S, Fillman R, Yandow S. The etiology of protrusio acetabuli Literature review from 1824 to 2006. *Acta Orthop Belg* 2006; **72**:524–529.
- Solomon LB, Lee YC, Callary SA, Beck M, Howie DW. Anatomy of piriformis, obturator internus and obturator externus. *J Bone Joint Surg [Br]* 2010; **92-B**:1317–1324.